

Planning, placing and restoring dental implants: an image-driven process

The loss of teeth impacts on a patient's everyday life and more and more people now opt for the permanence of dental implants over removable dentures. This article details how implants can be planned with the help of computed tomography scanning and placed using surgical guides derived from these images.

As a person ages, the accumulation of wear and tear often results in the loss of teeth. Sometimes teeth are knocked out through trauma, but more often they simply fall out through neglect or are extracted because they are no longer viable. This loss of teeth impacts on the patient's everyday life as their speech, appearance and food choices are affected. Although removable dentures are an obvious solution, many people opt for the permanence of dental implants. This article explains how dental implants can be planned with the help of computed tomography (CT) scanning and placed using surgical drill guides derived from the CT images. CT scans are so extremely accurate that in many cases the restoration (crowns or bridgework) can be installed at the time of implant surgery as well.

Restorations based on dental implants hold many advantages over conventional dentures. First, they remain permanently in the patient's mouth, avoiding the need to remove and clean them daily. More importantly, implants prevent the characteristic bone resorption associated with loss of teeth. They therefore remove the problem of denture loosening, which causes considerable social anxiety, and subsequent relining, which patients find irritating and time-consuming. In practice, each implant can sup-

port a number of prosthetic teeth. This means that it is not necessary to replace every missing tooth, which obviously cuts down the overall cost of the procedure for the patient.

The implant process

The process typically falls into three broad stages once the decision has been made to consider dental implants as an option. First, a diagnostic wax-up is made by the dental laboratory, to check the functionality and aesthetics of the proposed restoration and gain the patient's approval. Next, the patient is CT-scanned wearing a special plastic stent containing radio-opaque markers, to indicate the ideal locations of the proposed implants. These reference points can be in the form of a radio-opaque base plate or radio-opaque teeth or just markers showing the ideal points at which the abutments of the implants will be located. These markers show up on the CT images and simplify the detailed planning process (*Figures*

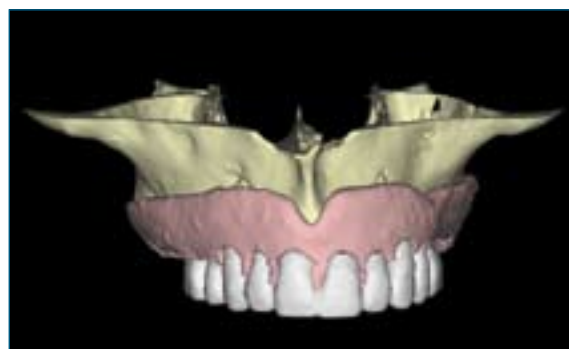


Figure 1. A scanning stent incorporating both radio-opaque baseplate and radio-opaque teeth.

William Hale, Barry Chandler and Anthony Reynolds
Image Diagnostic Technology Ltd

Email: rar@ctscan.co.uk

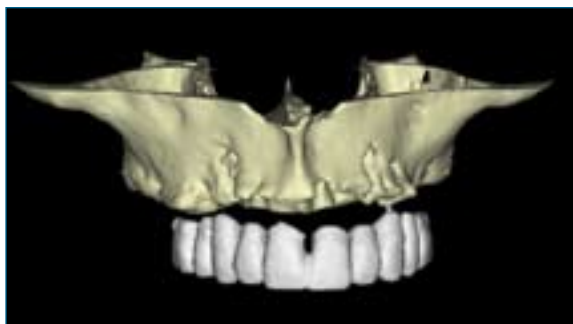

Figure 2. A scanning stent with radio-opaque teeth, without a baseplate.

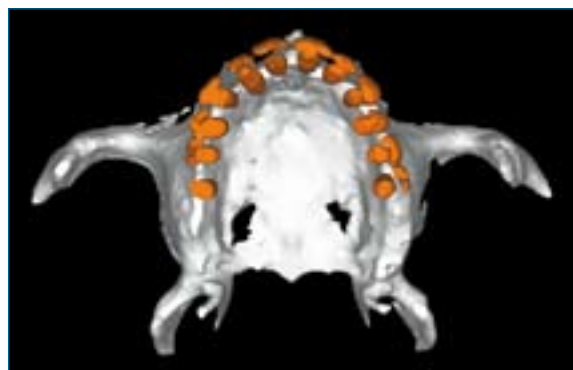


Figure 3. A maxilla stent with markers.

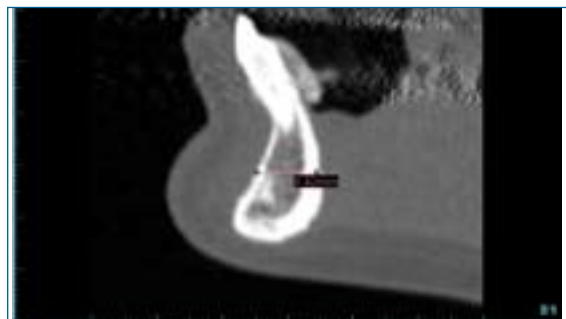


Figure 4. A cross-section image illustrating a buccal-lingual measurement.

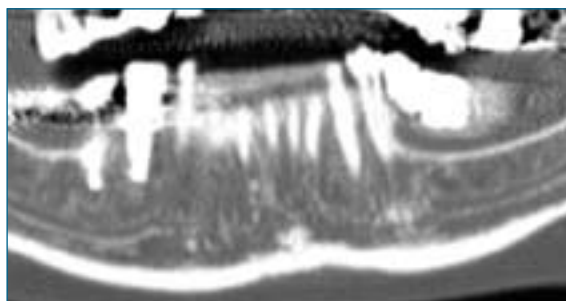


Figure 5. A panoramic view of the mandible clearly displaying the inferior alveolar nerve (the nerve that runs down the centre of the mandible).

1–3). After the CT scan the dentist determines the exact implant locations using SimPlant (Materialise Dental NV, Belgium), coDiagnostiX (IVS Solutions AG, Germany), ImplantMaster (iDent Imaging Inc, Israel), Procera (Nobel Biocare AB, Sweden) or similar dental implant planning software.

Dental implantology can be compared to drilling holes in the wall to put up shelves. When drilling into the wall you need to know three things:

- If the wall is sturdy enough to support the fixtures. This is analogous to ensuring that the bone is dense enough to support the dental implant.
- If there are electrical cables or water pipes in the wall to be avoided. This is similar to having to avoiding the inferior alveolar nerve, sinus or any other sensitive anatomy.
- The holes in the shelves' fixings can be used as a template to make sure that the holes in the wall are drilled in exactly the right places for the screws. This is similar to using a SurgiGuide to drill the osteotomies in precisely the right locations.

From the dentist's computerized treatment plan a SurgiGuide (surgical drill guide; Materialise NV, Belgium) is manufactured, with drilling cylinders corresponding in size and location to the 'virtual implants' placed by the dentist on their computer screen. Finally, the drill guide is used during surgery

to prepare the osteotomies and place the implants very accurately – so accurately that in many cases the restoration (bridge) can be made by the dental laboratory before the surgery takes place, confident that the implants will be placed in exactly the right places to make it fit.

CT versus dental panoramic tomography

Why is it necessary to go to considerable trouble to send a patient to a hospital for a CT scan when

EXAMPLES OF SOFTWARE USED IN IMPLANT PLANNING

SimPlant	Materialise NV
coDiagnostiX	IVS Solutions
Implant Master	iDent Imaging Inc
Procera	Nobel Biocare AB

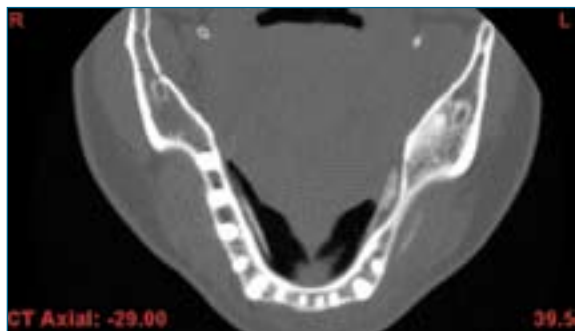

Figure 6. A transaxial slice of the mandible. This patient has three implants on the right side of the mandible.

practices commonly have their own x-ray capacity in the form of dental panoramic tomography (DPT) machines? The usual answer is that the information obtained from an DPT machine is in two dimensions only. DPTs only provide information about bone height—they don't provide any indication of bone width (in the buccal-lingual dimension) or the quality of the bone into which the implants will be placed. Also, DPTs have been known to introduce serious errors in estimating implant length and the distance to critical structures such as the inferior alveolar nerve (Sonick et al, 1994). However, a second answer is that more and more dentists are installing cone beam CT scanners within their dental practices,

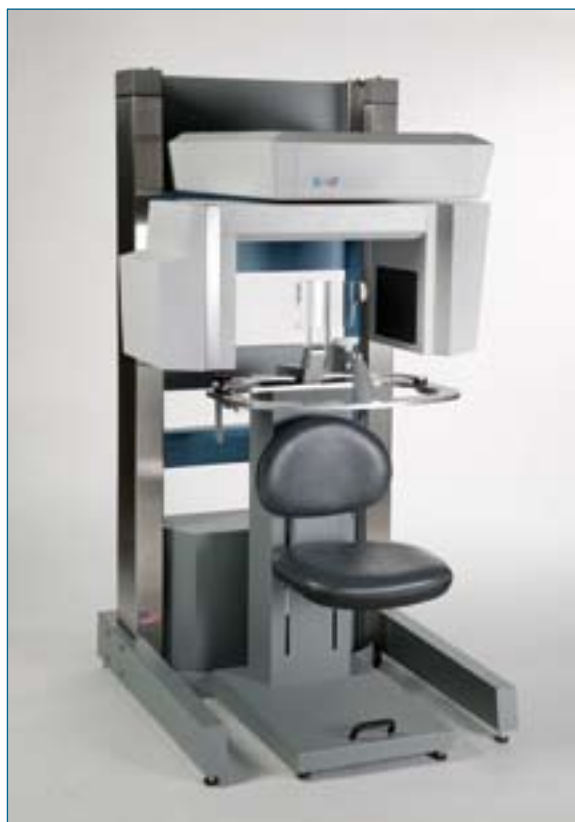

Figure 7. The i-CAT cone beam CT scanner (Imaging Sciences International).

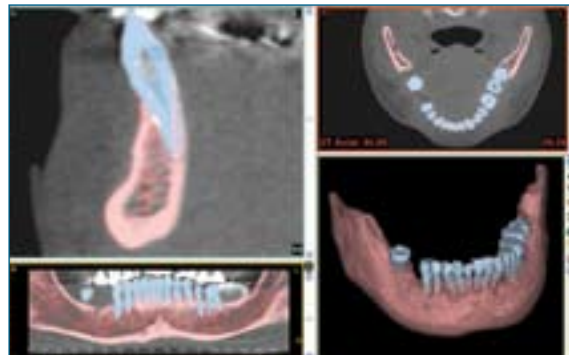


Figure 8. Segmentation: Here the teeth and maxilla are identified as blue and pink regions, respectively.

therefore combining the detail of CT images with the speed and convenience of DPT machines.

A CT scanner in the dental practice

A CT scan is essentially a series of cross-sectional x-ray images taken at very narrow spacing (0.5mm or less) through the patient. These slices are then stacked on top of each other to produce a three dimensional (3D) dataset that can be manipulated further (through a process known as reformatting) to produce 'new images from old' and a number of products that can be helpful before and during surgery. Unlike two-dimensional (2D) x-rays, information on bone density as well as distance measurements in buccal-lingual, mesial-distal and superior-inferior directions can be obtained accurately (Figures 4–6).

CT machines designed for hospitals are not only expensive but are also very large and complex. Sending the patient to a hospital is a time-consuming administrative procedure for the practice and an annoyance for the patient in terms of travel and waiting for an appointment slot to become available.

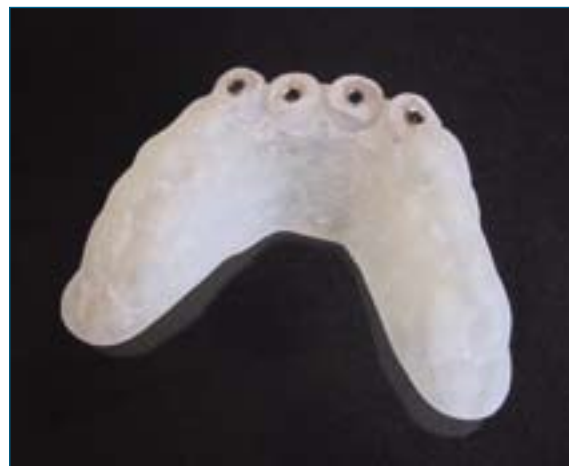

Figure 9. A tooth-supported SurgiGuide with cylinders for drilling four osteotomies.

Cone beam CT scanners

A new generation of CT scanners, known as cone beam CT or CBCT scanners, are designed specifically for in-house dental scans. Machines such as the i-CAT (Figure 7), NewTom (QR Srl, Italy) and Accuitomo (J Morita Manufacturing Corp, Japan) can be situated in the surgery and operated by a specially trained dental nurse, which removes the hospital from the equation. Moreover, the patient is exposed to a lower dose of radiation than a traditional hospital CT scan (see below).

Typical doses of radiation

Dental x-rays are classed as ionizing radiation. This means that the x-rays have enough energy to alter cellular structures and DNA molecules within the body. The most dangerous scenario comes about when an x-ray splits the DNA within a given cell and the double helix repairs itself incorrectly. The cell might no longer be able to regulate its self-replication processes, potentially resulting in a cancer. Consequently, it is vitally important that patients are exposed to the smallest quantity of radiation possible. In practice this is achieved by using the lowest exposure factors consistent with the diagnostic requirements, taking the minimum number of x-rays that are strictly necessary, and only imaging the smallest possible region of the body.

Dental radiation doses may be compared by expressing them in microSieverts (μSv). This takes into account the volume of tissue irradiated and also the fact that some body tissues are more prone to radiation damage than others.

A single dental periapical or bitewing x-ray taken with digital detectors and rectangular collimation—about $4\mu\text{Sv}$ per film if round collimators and E-Speed film are used (FGDP, 2004). A full mouth set of 20 periapicals therefore requires $20\text{--}80\mu\text{Sv}$. A typical DPT requires about $20\mu\text{Sv}$ and an i-CAT cone beam CT scan requires about $70\mu\text{Sv}$. By contrast, a typical dental CT scan carried out at a hospital requires about $300\mu\text{Sv}$ per dental arch.

However, one should always bear in mind that the doses involved in dental imaging procedures (even hospital CT scans) are very low in comparison to the $2200\mu\text{Sv}$ on average that everyone in the UK receives from natural background radiation every year.

Guided implant surgery

Guided implant surgery employs a technique dubbed 'reverse engineering.' This involves starting with a representation of the final result and working backwards to see how it can be achieved. The representation of

the final result takes the form of the radio-opaque scanning stent which has been manufactured to be visible on the CT scan. This is achieved by mixing the liquid acrylic used to make the stent with barium sulphate powder, which is a radio-opaque substance.

A typical case

Let's take a closer look at a typical case scanned at the dental practice with an i-CAT scanner. After the patient has been scanned, the CT dataset is viewed and analysed on the display monitor attached to the i-CAT. For more detailed analysis the data can be read into implant planning software such as SimPlant. The analysis begins by colouring the bone, teeth, stent and any other objects according to their CT density. This process is called segmentation and the resulting coloured objects are used to create an onscreen 3D model of the patient's anatomy (Figure 8).

SimPlant software allows the path of the inferior alveolar nerve to be traced and highlighted. This is vital because if the nerve is damaged during implant surgery, the patient may suffer from facial paraesthesia. Once the nerve has been highlighted the SimPlant software will detect collisions and warn the user if an implant is planned too close to the alveolar nerve.

The implantologist can use the software to experiment with various implant types and explore the best angle and depths for their insertion. The software incorporates exact dimensional information as well as the densities of all of the objects in the scan. The surgery can be planned in minute detail so the patient can receive the best possible results in the safest fashion.

Using the computerized treatment plan, the implantologist has the option of ordering two products that can directly help them at the time of surgery. First, a SurgiGuide can be ordered through the SimPlant software. These surgical drill guides are custom produced for each patient under computer control, from biocompatible acrylic resin, through a process known as stereolithography. SurgiGuides incorporate metal cylinders to constrain the dentist's drill and are manufactured to sit in a unique position on one or more of the patient's teeth, gums or bone. The implantologist is then able to drill through the cylinders, safe in the knowledge that he or she is drilling in exactly the required position (Figure 9).

The other option that can be ordered from the planned CT data is a rapid prototype model (RP model). This is a life-sized model of the patient's jaw and teeth, constructed from acrylic resin through the same process of stereolithography. These precise anatomical models are visual and tactile tools that

KEY POINTS

- Many people are now choosing the permanence of dental implants over removable dentures.
- Implants can be planned with the help of computed tomography (CT) scanning and placed accurately with guides derived from these images.
- A CT scan is essentially a series of cross-sectional x-ray images taken at very narrow spacing through the patient. The 'slices' are then stacked on top of each other to give a detailed 3D image
- A new generation of CT scanners (cone beam CT or CBCT scanners) have been designed specifically for in-house dental scans. These are situated in the surgery and can be operated by a specially trained dental nurse.

allow the rehearsal of complex maxillo-facial or orthognathic surgery.

SurgiGuides cannot be autoclaved but should be disinfected thoroughly before surgery. Classic SurgiGuides consist of a set of three surgical guides to aid in the correct preparation of the osteotomy sites. These are used in succession and are dubbed pilot, intermediate and final to correspond to the respective osteotomy drills. Each SurgiGuide has the top of its drill cylinders exactly 5 mm above the drilling surface. Therefore, the calculated drill depths must be increased by 5 mm from the planning stage. More complex SurgiGuides such as the SAFE system (Materialise NV) are able to regulate the depth of the drill as well as its location.

The three drilling stages prepare the holes into which the titanium implant fixtures will be placed. As the drilling is in progress, the bone heats up and irrigation is necessary for cooling purposes. The

SurgiGuides incorporate holes so that internal or external water irrigation can be used. After the fixtures have been placed the abutments and the prosthetic teeth or bridgework can be added.

Conclusion

Restorations based on dental implants hold many advantages over conventional dentures. The ultimate goal of the CT scan, planning software, and surgical drill guides is that the implants can have a higher chance of success both clinically and cosmetically and can be placed in a surgically safe environment.

FGDP (2004) *Selection Criteria for Dental Radiography*. Royal College of Surgeons of England, London:

Sonick M, Abrahams J, Faiella RA (1994) A comparison of the accuracy of periapical, panoramic, and computerized tomographic radiographs in locating the mandibular canal. *Int Oral Maxillofac Implants* 9: 455-460

FURTHER INFORMATION

IDT Ltd was founded specifically to address the difficulties in arranging and reformatting dental CT scans. In addition to our image reformatting service we train radiographers at hospitals, providing them with protocols specific to their CT scanner models, with a view to obtaining the best image quality at the lowest practical radiation dose. We also run seminars and courses to assist dentists and surgeons who are referring patients for CT scans and to help them in interpreting the results.

For more information please contact:

IDT Ltd, Unit GC, Westpoint, 36 Warple Way, London W3 0RG

Tel: 020 8600 3540

www.ctscan.co.uk